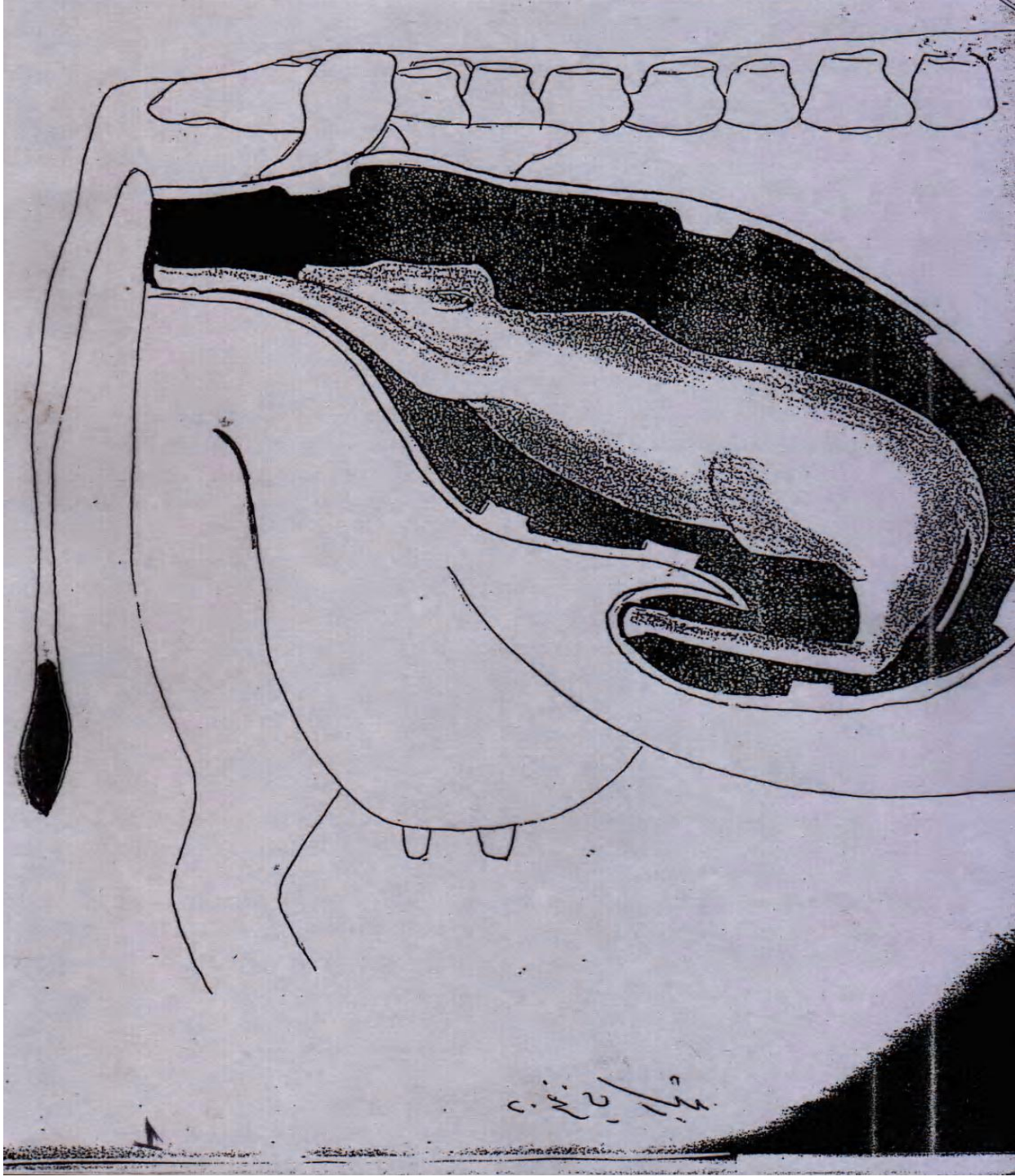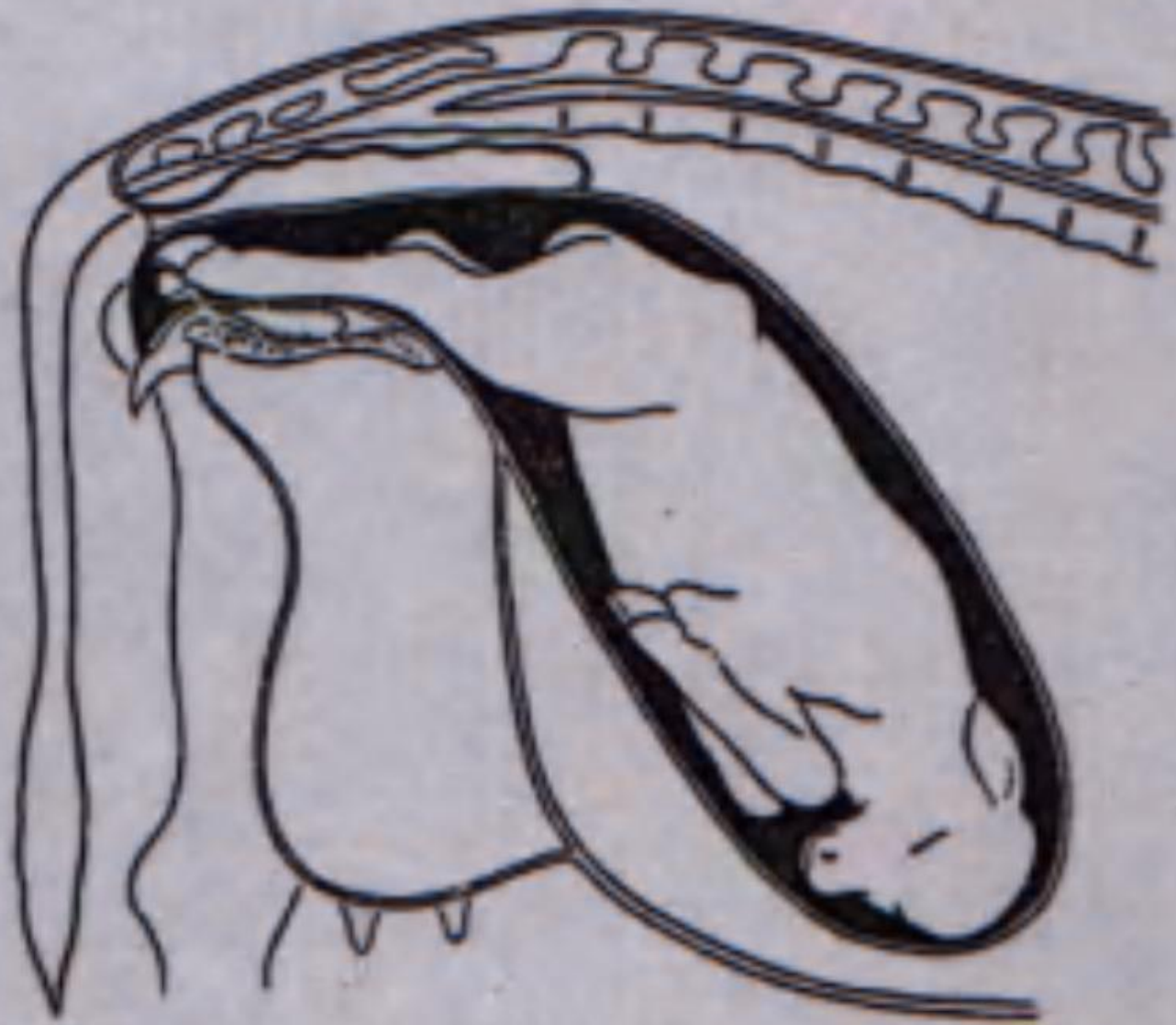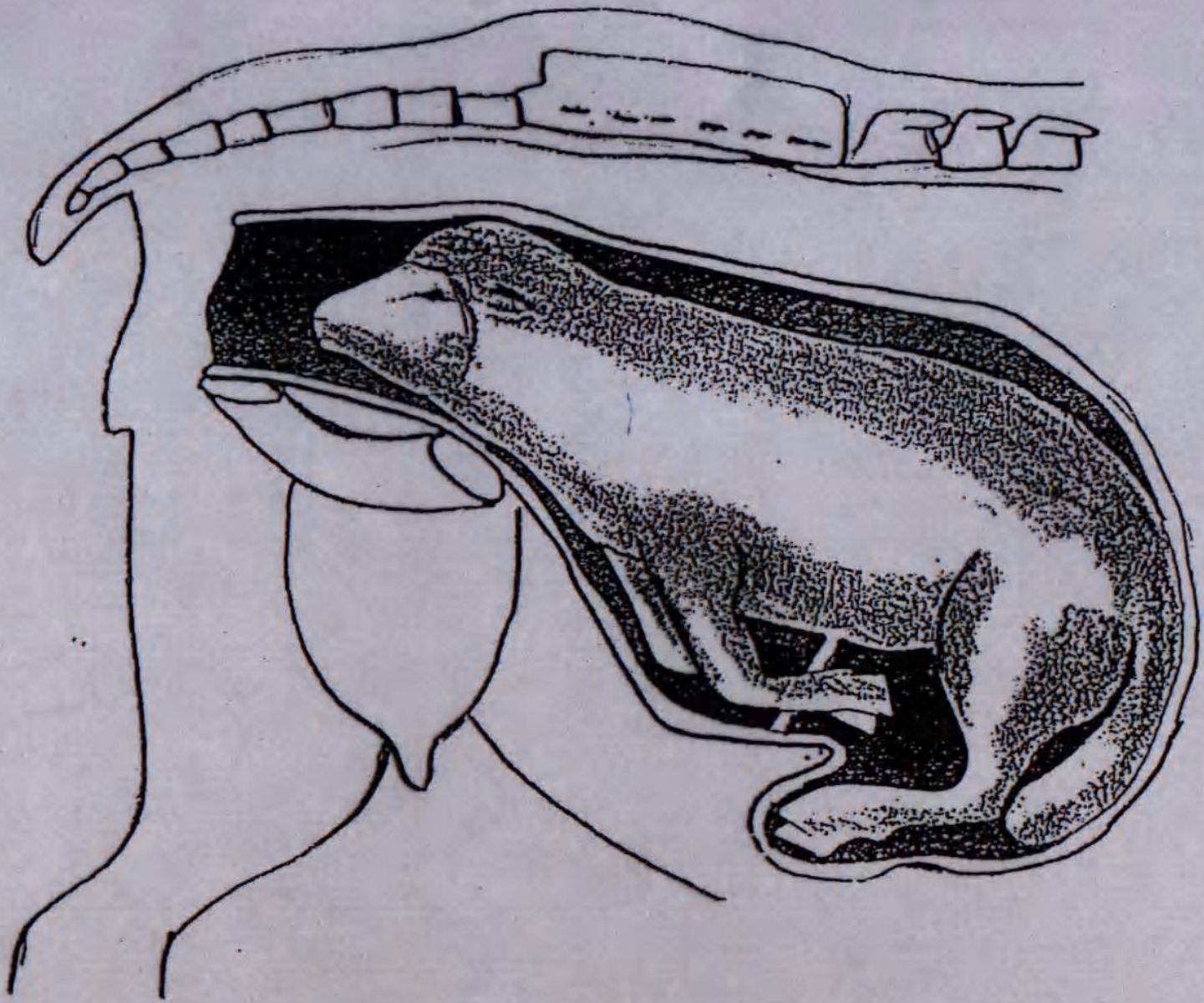


3/2/20

11



2



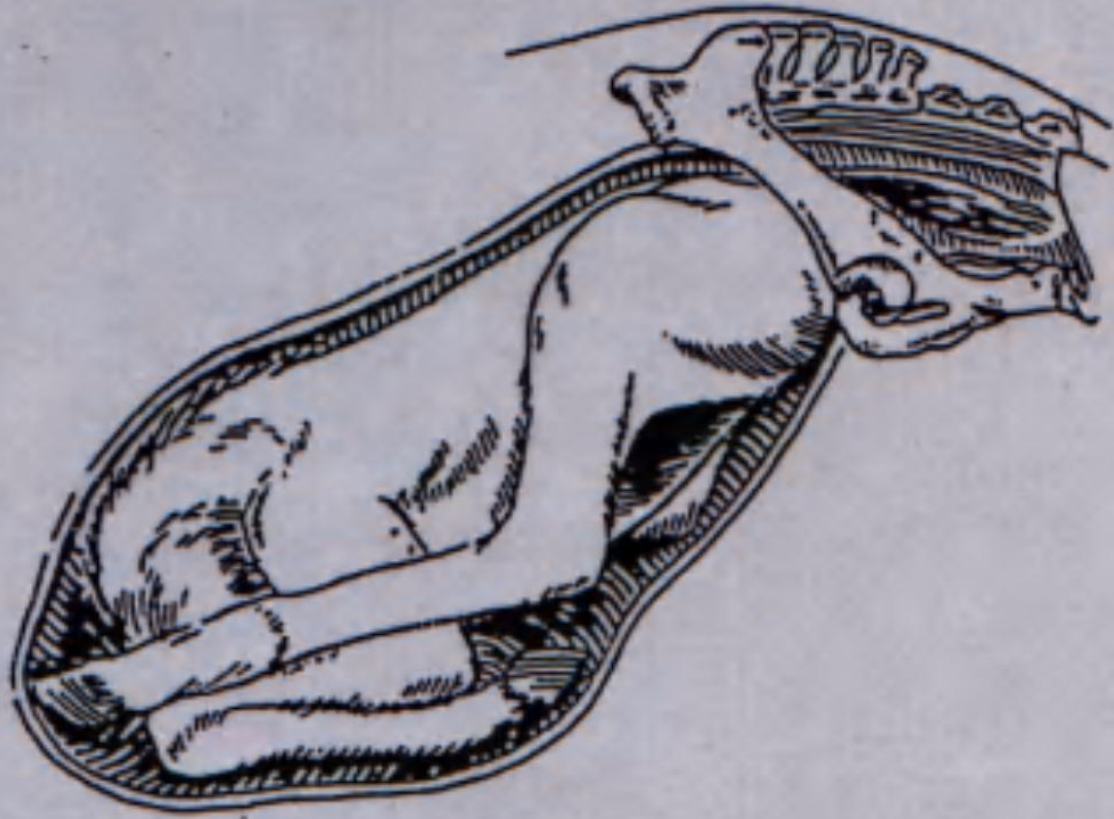
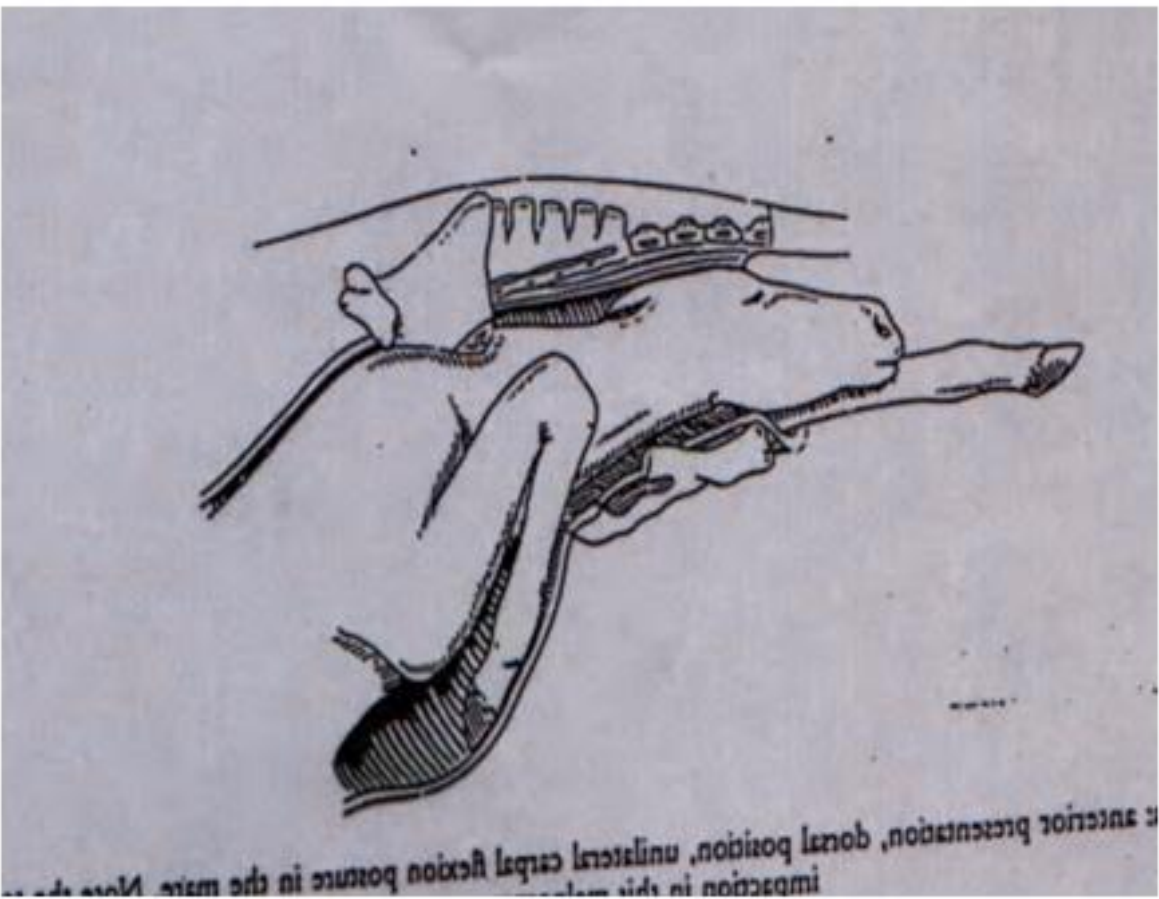
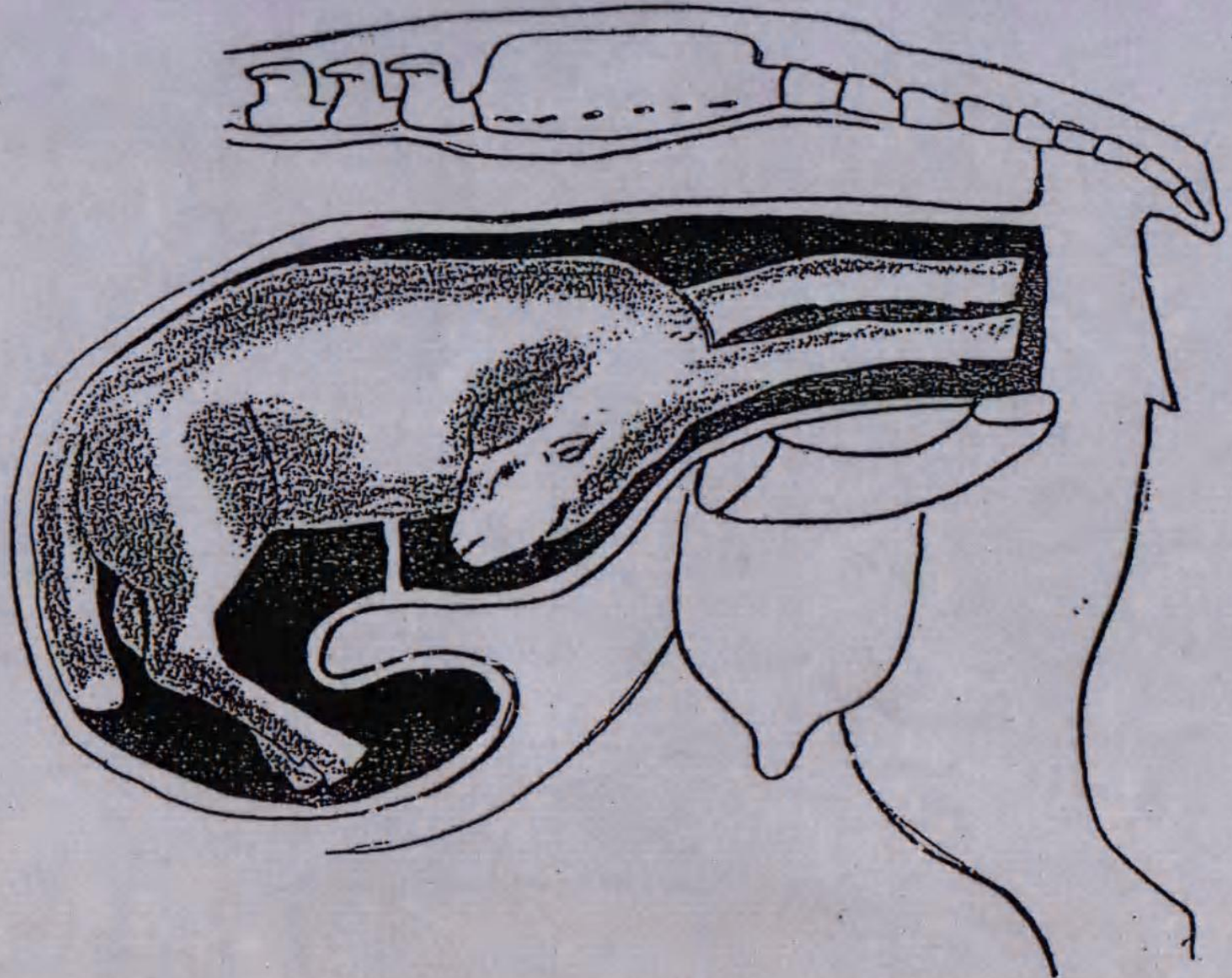
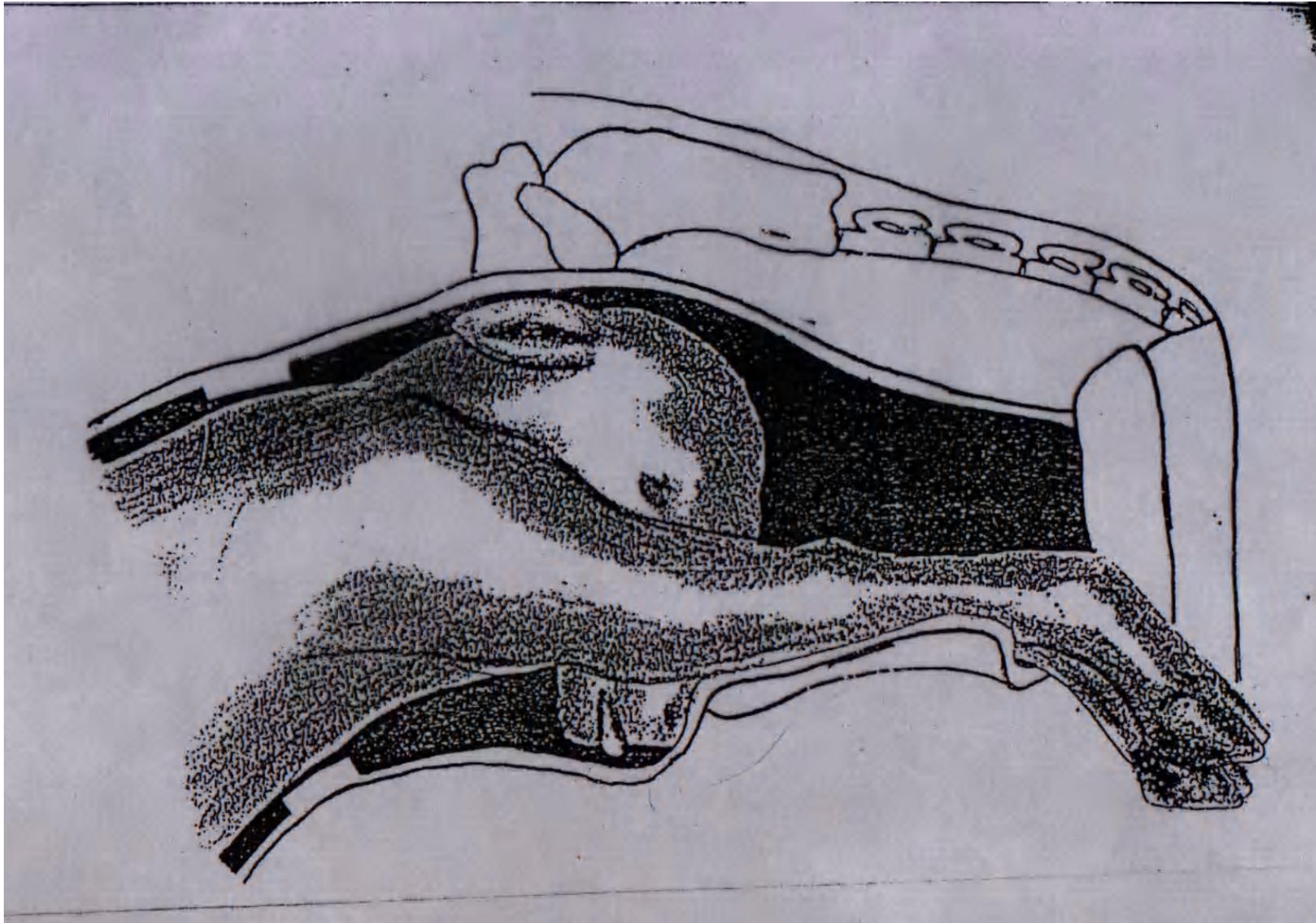


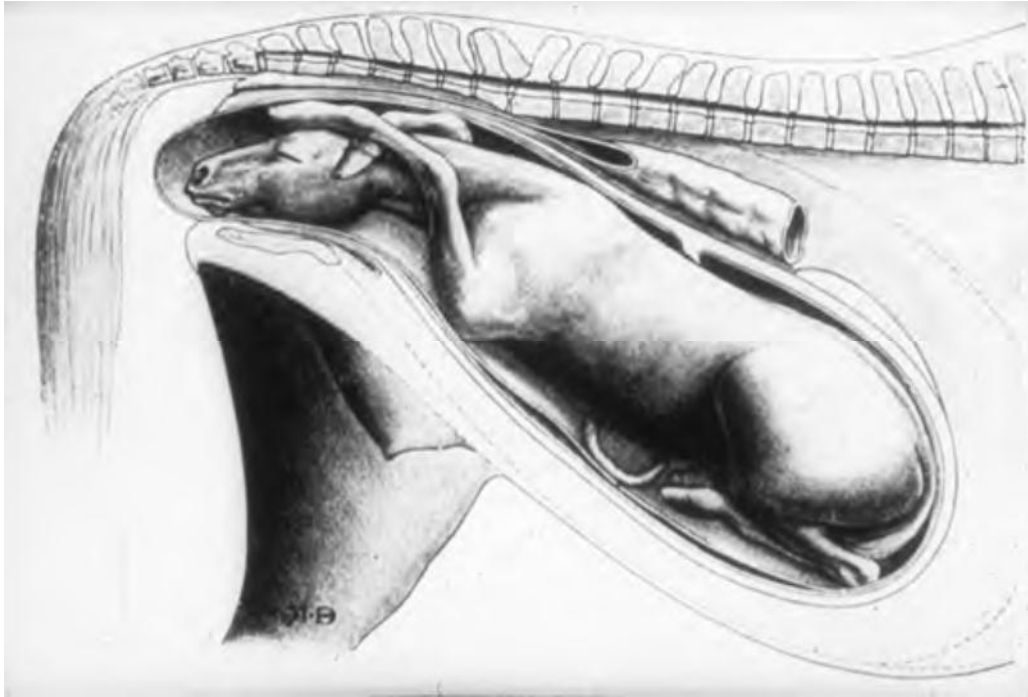
Fig. 14.20 Diagnosis: bilateral hip flexion posture in the mare
(breech presentation).












III



3

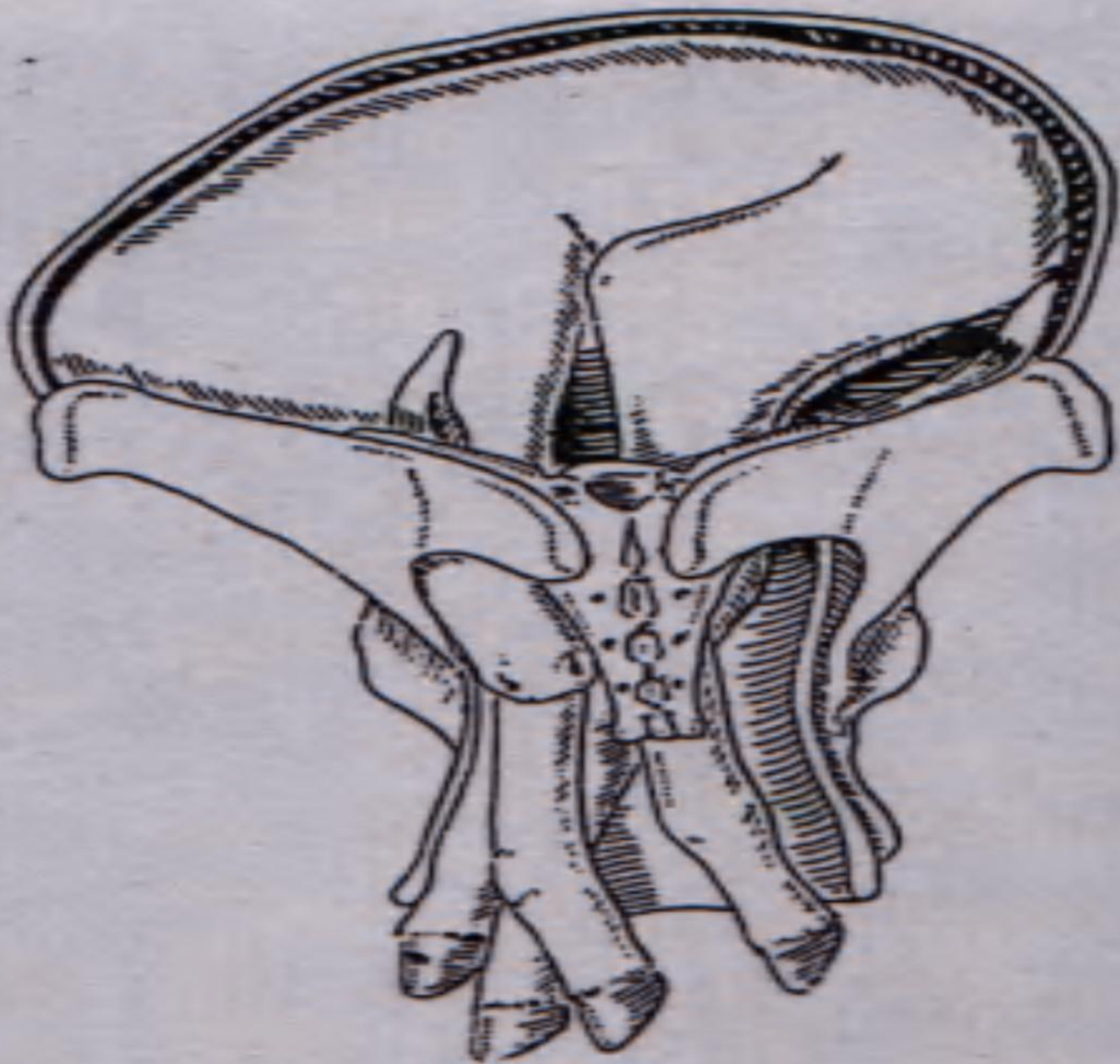
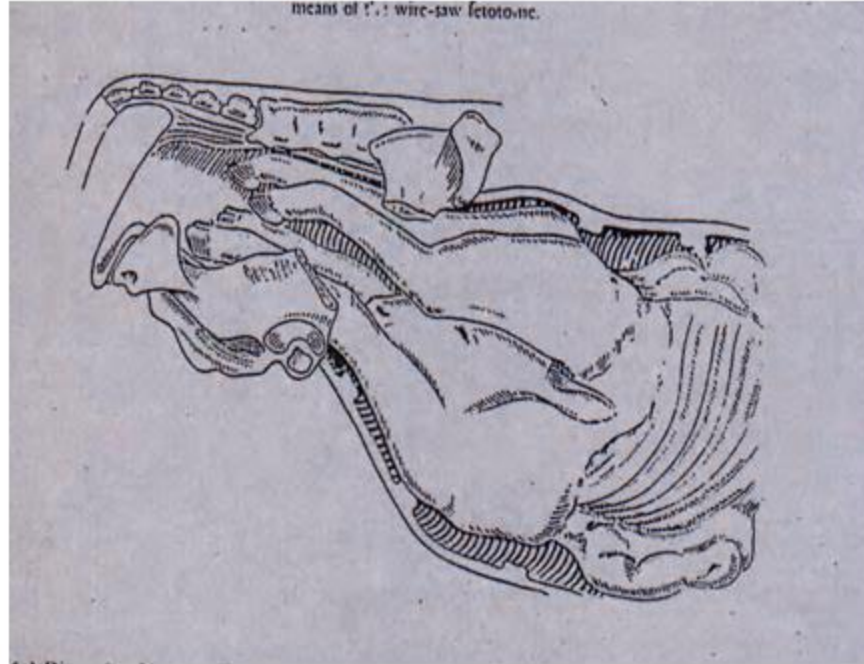
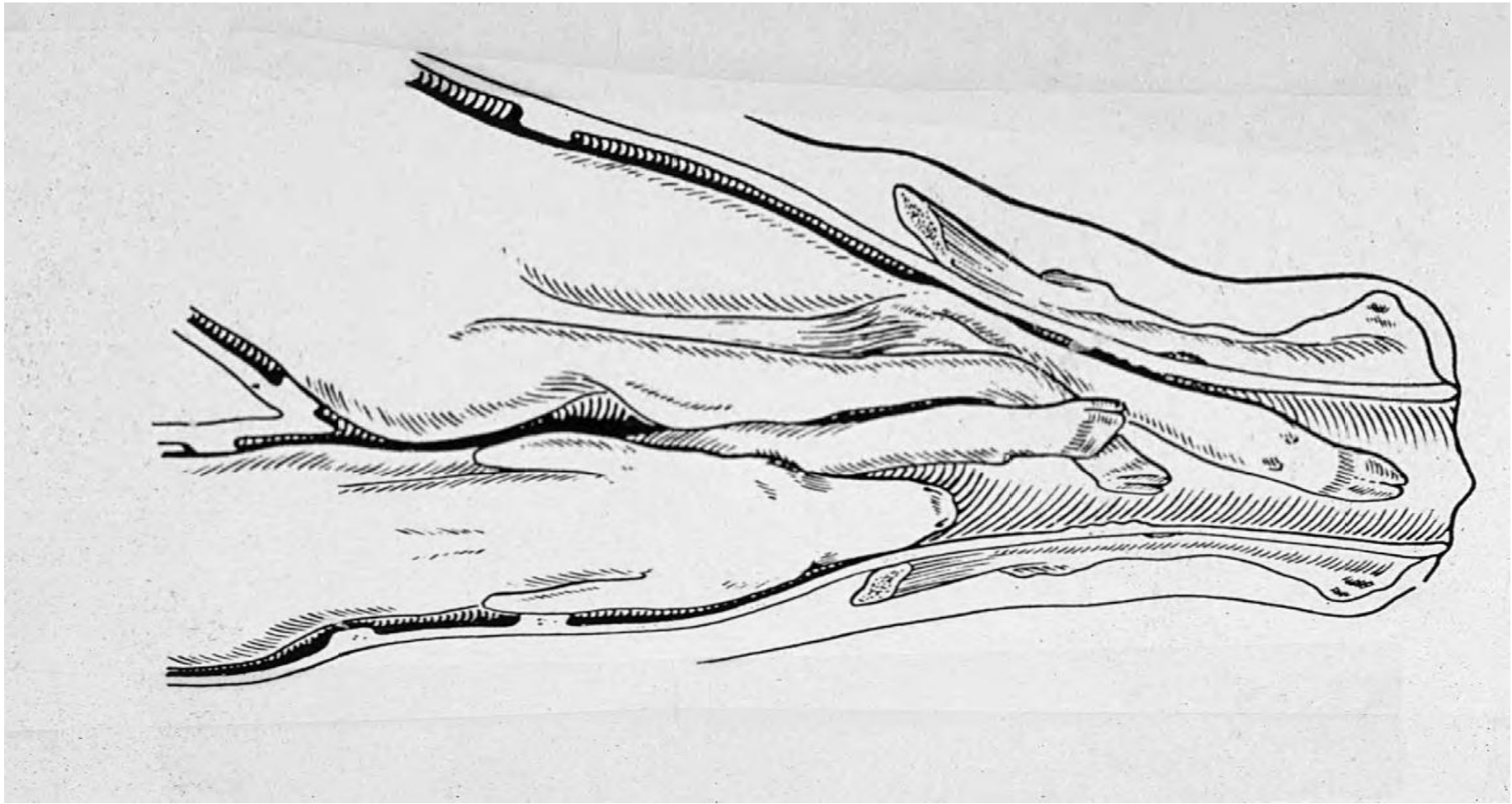


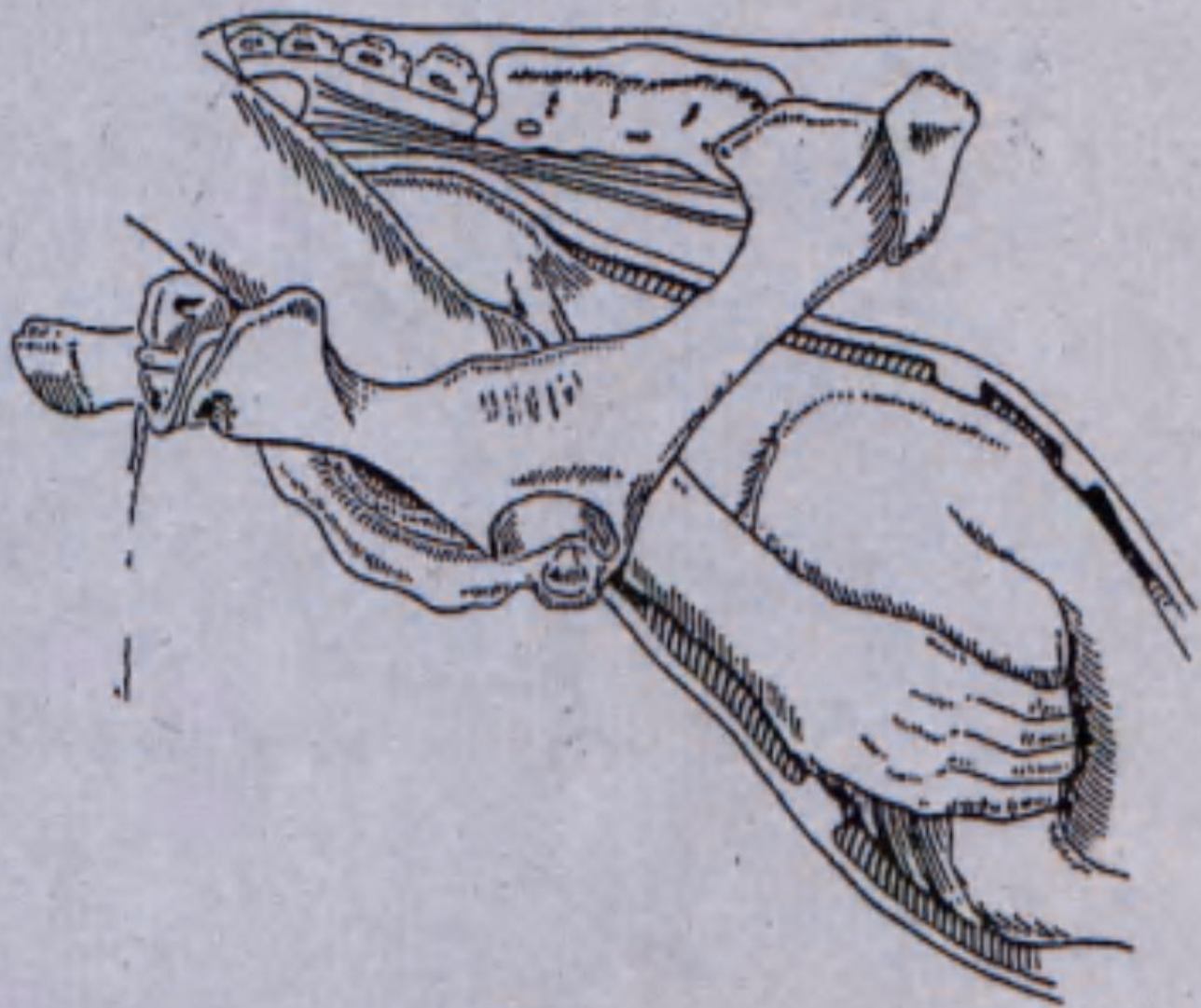
Fig. 15.5 Diagnosis: ventrotransverse presentation in the

means of the wire-saw fetotomy.





Other Disorders Associated with Parturition



Diagnosis: anterior presentation, dorsal position, unilateral shoulder flexion contracture (contracture of the right shoulder)

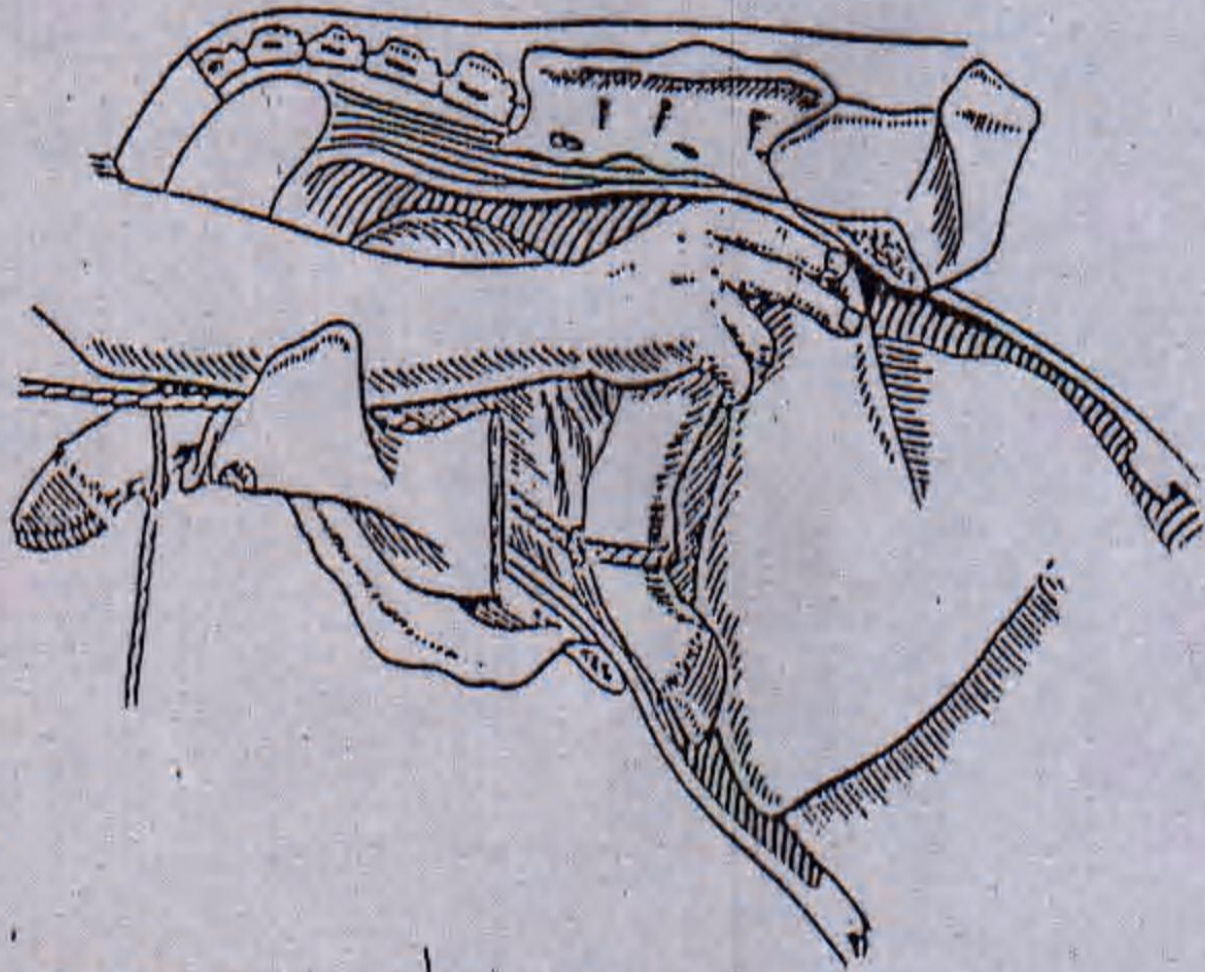


Fig. 14.2 Diagnosis: as in Figure 14.1. Correction using the hand and a digital snare.

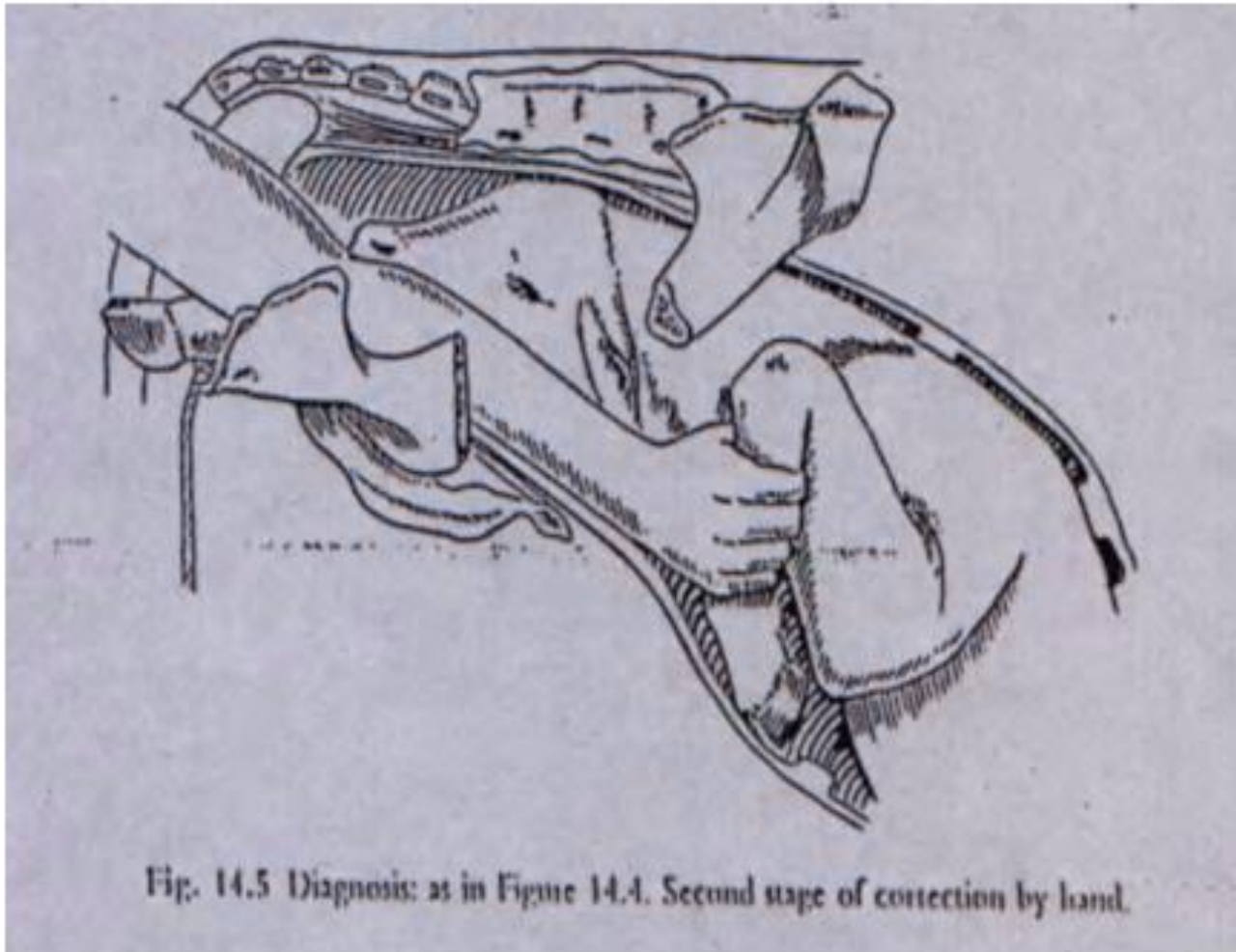


Fig. 14.5 Diagnosis: as in Figure 14.4. Second stage of correction by hand.

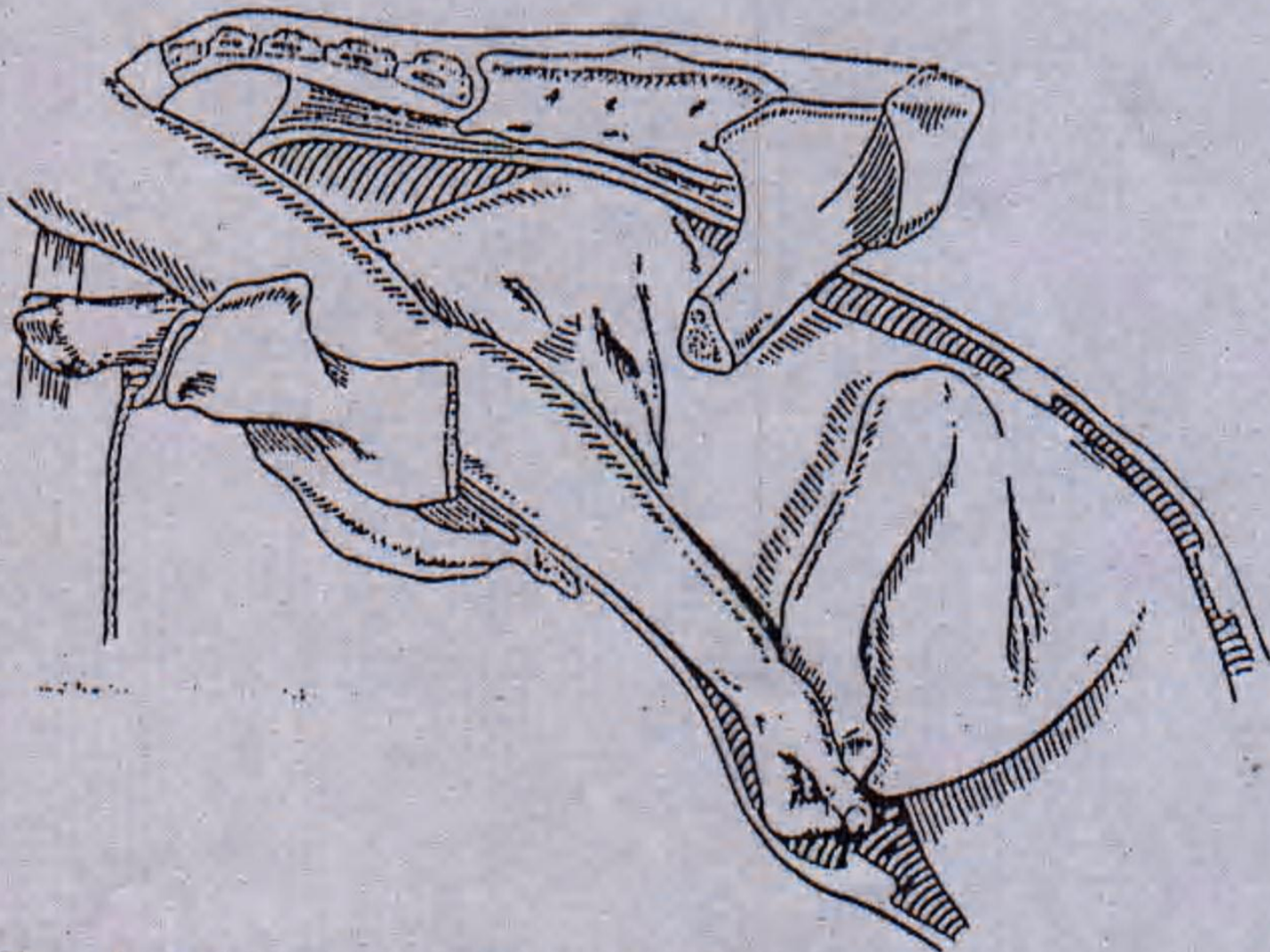


Fig. 14.3 Diagnosis: as in Figure 14.1. Correction by hand alone. Note the method of grasping

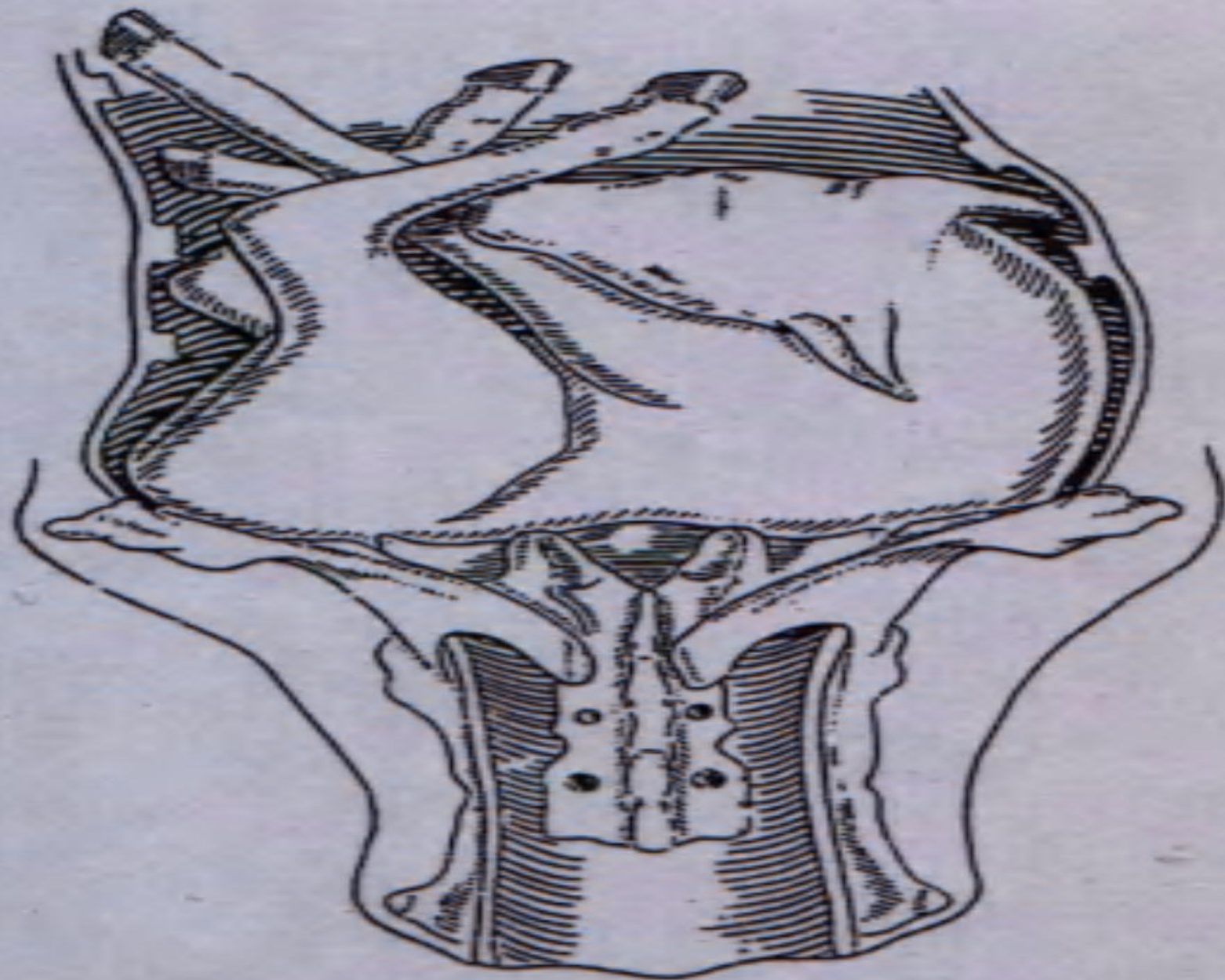


Fig. 15.4 Diagnosis: dorso-transverse presentation in the cow.



